



**PATIENT**

Sonny Piucci

**SPECIES**

Canine

**BREED**

Retriever Mix

**SEX**

Male Neutered

**AGE**

9 years

**WEIGHT**

67lbs

**PRESENTING CLINICAL SIGNS**

History: Sonny is referred to evaluate a heart murmur. He is presently doing well with a good appetite and normal activity level. On exam: NSR, grade III/VI murmur with PMI left apical area, PSS, lung fields clear, mm pink, moist, CRT<2. BP: 150 mmHg x 5 \*No sedation for study

**ECHOCARDIOGRAM FINDINGS**

2D, m-mode, color flow and Doppler imaging is available.

**Left ventricle:** The LV diameter is normal with adequate myocardial function. LV wall thicknesses are normal.

**Left atrium:** The left atrium is normal.

**Mitral valve:** The mitral valve is mildly thickened with no prolapse into the left atrial lumen. Mild anterior-directed mitral regurgitation with a normal velocity.

**Aortic valve/aorta:** The aortic valve is normal in morphology and mobility. Normal aortic outflow velocity; laminar flow. No aortic insufficiency.

**Right ventricle:** Normal right ventricular diameter and morphology indicating no overt evidence of pulmonary arterial hypertension.

**Right atrium:** Normal RA dimension.

**Tricuspid valve:** The tricuspid valve appears normal with no tricuspid regurgitation.

**Pulmonic valve/pulmonary artery:** The pulmonic valve is normal in morphology and mobility. No pulmonic insufficiency. Normal RVOT velocity; laminar flow.

**Pericardium/other:** No pericardial or pleural effusion noted. No obvious cardiac masses.

**Heart rhythm:** ECG reveals a sinus rhythm with an average HR of 150bpm.

**2-Dimensional Measurements**

Ao diam (cm)	2.4
LA diam (cm)	3.2
LA:Ao (Swe)	1.3
IVS thickness (cm)	1.1
LVID diastole (cm)	3.9
PW thickness (cm)	1.1
LVID systole (cm)	2.2
FS (%)	42

**Doppler Measurements**

PV Vmax (m/s)	0.9
AoV Vmax (m/s)	1.5
MR Vmax (m/s)	5.2
TR Vmax (m/s)	NA
TR PG (mmHg)	NA

**INTERPRETED BY**

Maggie Machen  
Lamy, DVM  
DACVIM (Cardiology)

**IMAGING**

**PERFORMED BY**

Pamela Harrigan,  
RDCS

**HOSPITAL NAME**

Mass Veterinary  
Services

**REFERRING VET**

Dr. Masloski

**INTERPRETATION OF THE FINDINGS**

The cause of the murmur is chronic degenerative valve disease causing mild mitral regurgitation. Lack of significant left atrial enlargement indicates the current risk for complication is low. No concurrent issues such as pulmonary hypertension are noted in this study.

Assessment of progression in the future will help predict long term prognosis, which is highly variable at this stage (B1).

**RECOMMENDATIONS**

- In an asymptomatic dog without significant left atrial enlargement, no cardiac medications are clearly indicated.
- Omega fatty acid supplementation and mild salt restriction may be of some long-term benefit.
- Anesthetic risk is considered mild if needed. Cardiac protective drug choices (opioid/benzodiazepine premedication, propofol or alfaxalone induction, isoflurane

**INVOICE**

32352

**DATE**

8/14/23



**PATIENT**  
Sonny Piucci

gas) are recommended. Pre-oxygenate for 5-10 minutes prior to induction. Monitor for arrhythmias, hypotension, and hypoxia both intra and post-operatively and intervene as necessary. Mild IV fluid restriction is recommended to avoid fluid overload. Avoid heart rate stimulating drugs such as atropine unless clinically indicated.

**SPECIES**  
Canine

- Monitor for development of a cough, labored breathing, exercise intolerance or collapse episodes.

**BREED**  
Retriever Mix

**PLAN**

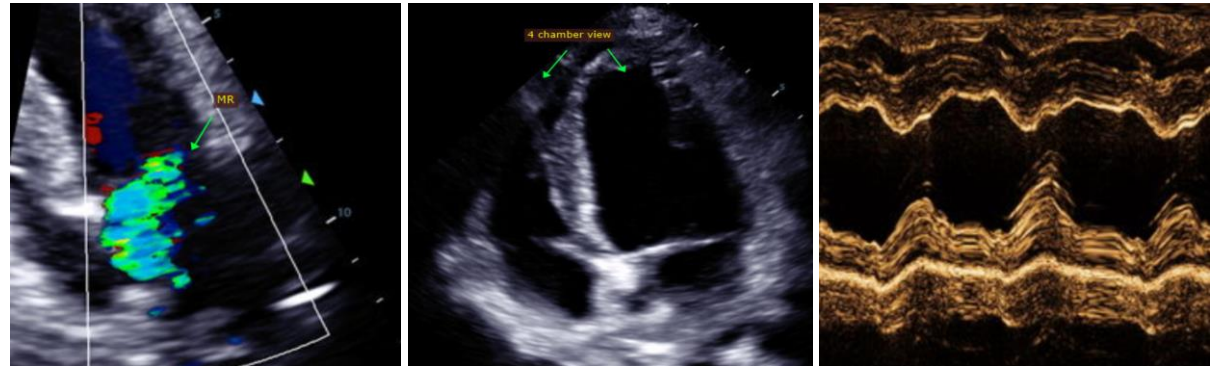
- Recommend conservative monitoring with a recheck echocardiogram in 6-12 months, sooner if any development of clinical signs.

**SEX**  
Male Neutered

**AGE**  
9 years

**WEIGHT**  
67lbs

**IMAGES**



**INTERPRETED BY**

Maggie Machen Lamy, DVM  
DACVIM (Cardiology)

The information and recommendations provided are based on the images presented by the referring veterinarian. No evaluation can be communicated regarding pathology that was not visible in the image/video clips provided.

Thank you for this referral. This report was generated using transcription software, and minor dictation errors may be present. If the clinical or image interpretation does not parallel your findings or if I can be of any further assistance, please contact me.

**IMAGING PERFORMED BY**

Pamela Harrigan, RDCS

**Maggie Machen Lamy, DVM**  
Diplomate of the American College of Veterinary Internal Medicine (Cardiology)  
info@sonopath.com

**HOSPITAL NAME**

Mass Veterinary Services

**Echocardiogram performed by:**

Pamela Harrigan, RDCS  
Pet Animal Ultrasound Service (4paus.com)

**REFERRING VET**

Dr. Masloski

**INVOICE**

32352

**DATE**

8/14/23